




Contents lists available at ScienceDirect

The Journal of Foot & Ankle Surgery

journal homepage: www.jfas.org

Original Research

A Review of 51 Talonavicular Joint Arthrodeses for Flexible Pes Valgus Deformity

Craig A. Camasta, DPM¹, Christopher R.D. Menke, DPM² Patrick B. Hall, DPM³

¹Fellow, American College of Foot and Ankle Surgeons; Attending Surgeon, Dekalb Medical, Decatur, GA; Faculty, The Podiatry Institute, Decatur, GA

²American College of Foot and Ankle Surgeons; Member Podiatry Institute; Private practice, Decatur, Georgia

³American College of Foot and Ankle Surgeons; Member Podiatry Institute; Private practice, Baton Rouge, LA

ARTICLE INFO

Level of Clinical Evidence: 2

Keywords:

arthrodesis
navicular
outcome
radiograph
talus
visual analog scale

ABSTRACT

The purpose of this study was to evaluate the radiographic and clinical outcomes of isolated talonavicular arthrodesis in the treatment of the flexible pes valgus foot type. Retrospectively, 51 consecutive isolated talonavicular arthrodeses in 41 patients were evaluated. The mean patient age was 47 (range 9 to 72) years, and the mean follow-up duration was 43.3 (range 11 to 113) months. The mean 10-cm categorical pain score before the surgery was 7.60 ± 2.37 , and this improved to 1.90 ± 2.38 postoperatively, and this difference was statistically significant ($P < .001$). We also measured the preoperative and postoperative percent of talar uncovering, calcaneocuboid angle, Kite's angle, talar dome height, calcaneal inclination angle, and Meary's angle, and observed statistically significant ($P < .001$) improvements in all of these. Fifty-one (100%) of the cases progressed to radiographic osseous union, although 2 (3.92%) of the cases were considered delayed unions. Moreover, 4 (7.84%) of the cases displayed juxta-articular arthrosis postoperatively, and 2 (3.9%) cases developed transfer pain to the lateral column. The authors concluded that isolated talonavicular arthrodesis is a safe and effective procedure for the treatment of painful pes valgus deformity.

© 2010 by the American College of Foot and Ankle Surgeons. Published by Elsevier Inc. All rights reserved.

The painful pes planovalgus foot type involves a wide spectrum of deformities. Possible causes for the symptomatic pes valgus deformity include posterior tibial tendon dysfunction, subluxation of the talus, triceps surae or isolated gastrocnemius equinus, traumatic tendon rupture, ligament laxity, and various neuromuscular imbalances (1, 2). Moreover, detailed discussion of the anatomy and pathophysiology of the symptomatic pes planovalgus deformity has been thoroughly described in the literature (3–9). This deformity has been described as involving all 3 planes of the foot, and has been termed “peritalar subluxation” because of the prominent subluxation of the talonavicular (TN) and subtalar joints, which is typically a central part of the deformity (10). Collapsing pes valgus deformity includes the loss of medial arch height, forefoot abduction, hindfoot valgus, and, most importantly, pain, discomfort, and functional weight-bearing limitations (11). A variety of joint-sparing, arthrodesis, and combination procedures have been described for the treatment of the painful pes valgus deformity that warrants surgical intervention (12–17). Interestingly, some previous authors have indicated the need for further research regarding the usefulness of isolated TN arthrodesis in this

setting (18, 19). In the current retrospective cohort investigation, the authors assessed the effectiveness of an isolated TN arthrodesis for the surgical management of the painful collapsing pes valgus deformity using pre- and postoperative visual analog scale (VAS) pain scores and radiographic measurements.

Patients and Methods

A retrospective chart review was completed by one of the authors (C.R.D.M.) for all patients treated by the senior author (C.A.C.) between May 1998 and December 2006. Patients who underwent TN arthrodesis for reasons other than flexible pes valgus deformity were excluded. Patients having other medial column stabilization or lateral column lengthening procedures in addition to the TN fusion were also excluded from this study. The only adjunctive procedures included within this study were gastrocnemius recessions, Achilles tendon lengthenings, and forefoot corrective procedures, leaving the TN fusion as the isolated midfoot-hindfoot fusion. As part of the routine preoperative assessment, patients were asked to rate their pain on a 10-point categorical pain score, wherein 0 represented no pain and 10 represented the worst pain that the patient could imagine. Postoperatively, patients were contacted by telephone interview and again asked to rate their level of pain using the same categorical scale. A follow-up objective, clinical evaluation was not performed, beyond the information that already existed in the medical record. At the time of the follow-up interview, moreover, we asked the patients if they were, overall, satisfied or dissatisfied with the outcome of their foot surgery.

In addition to the subjective assessment of pain, a number of radiographic variables were measured on the pre- and postoperative weight-bearing radiographs. Specifically, the radiographic analyses involved pre- and postoperative radiographs that were present in the medical record up to the time of the last follow-up evaluation, including the last set of preoperative radiographs and the final set of postoperative radiographs.

Financial Disclosure: None reported.

Conflicts of Interest: None reported.

Address correspondence to Christopher R. D. Menke, DPM, American College of Foot and Ankle Surgeons; Member Podiatry Institute, 2701 North Decatur Road, Decatur, GA 30033.

E-mail address: crmenke@yahoo.com (C. R. D. Menke).

Postoperative osseous union was determined by the radiographic presence of trabeculation across the TN joint on all 3 standard radiographs (anteroposterior, lateral, and medial oblique). Delayed union was defined as failure to demonstrate progressive changes consistent with arthrodesis after the 3-month postoperative interval. On the lateral radiograph talar dome height, calcaneal inclination angle and talar–first metatarsal angle were measured preoperatively and at various times during the postoperative period. On the dorsoplantar (DP) radiograph the talocalcaneal angle, cuboid abduction angle, and percentage of talar head uncovering were compared preoperatively and at various times during the postoperative period. All of the radiographic measurements were made in a fashion consistent with previously described methods (19, 20).

The operative intervention was carried out using a combination of a mid-calf pneumatic tourniquet and 0.25% bupivacaine with epinephrine (1:200,000) for hemostasis. A 5-cm medially placed, linear incision was made from the tip of the medial malleolus to the navicular-medial cuneiform joint. A linear incision was made through the capsular layer and all soft tissue and ligamentous attachments were dissected off of the TN joint. The tibialis posterior tendon was preserved, except for one case involving a complete rupture in which the tendon was excised from its insertion. Degeneration of the posterior tibialis tendon was not routinely evaluated or repaired. A small joint distractor was placed dorsally over the TN joint to allow for contoured joint resection without obscuring visualization. Joint resection was accomplished with rongeur, curettes, and power burs. The joint was fixated with 1 of 3 techniques: (1) two 4.0-mm partially threaded cancellous screws in a distal-to-proximal orientation, (2) a 2-hole one-third tubular plate fixated with two 4.0-mm fully threaded cancellous screws oriented eccentrically for compression, or (3) a 4-hole titanium locking H-plate. If present, ankle equinus was addressed in a variety of different ways. For patients with isolated gastrocnemius equinus, a gastrocnemius lengthening as described by Vulpus and Stoffel (21) was performed through a posteromedial incision with the patient supine and the leg externally rotated. For patients with gastrosoleal equinus, an open tendoAchillis lengthening (TAL) was performed through a medial incision creating a sagittal plane Z-lengthening. In all of the cases, the foot was initially placed in a compressive dressing with a posterior splint in a neutral position following the operation. In the postoperative phase, initial wound inspection was performed 7 to 10 days following the operation. The patient was placed in a permanent dressing consisting of either a posterior splint or a hard Jones compression dressing and remained non-weight bearing for 6 to 8 weeks. Protected weight bearing was initiated 6 to 8 weeks postoperatively, and full weight bearing in regular shoe gear routinely began 10 to 12 weeks postoperatively.

The data were abstracted from the medical records and the follow-up patient interviews, and stored on a personal computer running Microsoft Excel 2002 SP-2 (Microsoft Corporation, Redmond, WA). The data were inspected with an emphasis put on the data type and distribution. Descriptive analyses, repeated measures analysis of variance (ANOVA), and statistical comparisons were performed by Jeffery S. Kane, PhD, using a personal computer and SPSS v. 15 (SPSS, Inc., Chicago, IL). All outcome variables were analyzed using a within-subjects (preoperative versus postoperative) design, and statistical significance was defined at the 5% ($P \leq .05$) level.

Results

Review of the medical records revealed 68 patients who underwent TN fusion for a variety of disorders. After excluding patients who did not meet the inclusion criteria, records for 62 feet in 52 patients were retained for further consideration. The preoperative diagnoses of those considered were painful collapsed pes valgus deformity (52 [83.87%] feet), tibialis posterior tendon rupture (4 [6.45%] feet), and failed previous subtalar joint implant (6 [9.68%] feet). Only 41 (78.85%) of the 52 patients completed the postoperative follow-up interview; 2 (3.85%) patients were deceased of unrelated causes, and we were unable to contact the remaining 9 (17.31%) patients. After excluding those patients who did not complete the postoperative follow-up interview, a total of 51 feet in 41 patients were included in the final analyses. The descriptive results for the cohort are depicted in Table 1, and the results of the null hypothesis tests are depicted in Table 2. There were 15 (36.6%) males and 26 (63.4%) females with a mean age of 47 (range 9 to 72) years at the time of surgery, who were followed for a mean of 43.3 (range 11 to 113) months. Gastrocnemius recession was performed in 19 (37.26%) legs and open tendoAchillis lengthening in 13 (25.49%). Bone graft in the form of either allogeneic or autogenous bone was used in 10 (24.39%) cases; 6 (11.77%) of these involved the use of allogeneic and 4 (7.84%) autogenous bone graft material.

Table 1

Statistical description of the cohort (N = 51 feet in 41 patients)

Variable	Mean \pm SD or range, or count and %
Age, y, mean (range)	47 (9 to 72)
Female, count (63% of patients)	26 (63.42)
Gastrocnemius recession, count (46% of cases)	19 (37.26)
TendoAchillis lengthening, count (32% of cases)	13 (25.49)
Allogeneic bone graft, count (15% of cases)	6 (11.77)
Autogenous bone graft, count (10% of cases)	4 (7.84)
Preoperative (mean \pm SD)	
Talar uncovering (%)	40.14 \pm 15.75
Calcaneocuboid angle ($^{\circ}$)	28.33 \pm 10.78
Kite's angle ($^{\circ}$)	22.58 \pm 5.22
Talar dome height (mm)	7.09 \pm 0.92
Calcaneal inclination angle ($^{\circ}$)	10.42 \pm 7.05
Meary's angle ($^{\circ}$)	12.67 \pm 6.07
Pain score*	7.60 \pm 2.37
Postoperative (mean \pm SD)	
Talar uncovering (%)	1.00 \pm 2.36
Calcaneocuboid angle ($^{\circ}$)	5.80 \pm 4.99
Kite's angle ($^{\circ}$)	10.94 \pm 2.88
Talar dome height (mm)	7.74 \pm 0.77
Calcaneal inclination angle ($^{\circ}$)	18.94 \pm 6.05
Meary's angle ($^{\circ}$)	1.74 \pm 3.52
Pain score*	1.90 \pm 2.38
Delayed union (> 3 months postoperative), count (% of cases)	2 (3.92)
Satisfied with the results of the surgery, count (% of cases)	36 (70.59)
Duration of follow-up, mo, mean (range)	43.3 (11 to 113)

*Pain Score = 10-point categorical pain score.

In regard to the measurement of pain, the mean 10-point categorical scale score before surgery was 7.600 ± 2.367 , and this improved postoperatively to 1.900 ± 2.384 ; this change was statistically significant ($P < .001$) (Table 2). In regard to the binary, subjective outcome of overall satisfaction with the results of the TN fusion surgery, 87.81% (36/41) of the patients stated that they were satisfied with the surgery and would undergo the procedure again. Three (7.32%) patients were not satisfied with the outcome of the surgery, and indicated that they would not repeat the foot surgery. One (2.44%) of these was a female who suffered with rheumatoid arthritis and experienced substantial postoperative pain and abnormal motion involving her knees and lumbosacral spine. The other 2 (4.89%) were male patients who described transfer of pain to the lateral aspect of the foot and, of these patients, 1 (2.44%) was a workers compensation patient who, at last follow-up, was participating in a pain management program.

All of the radiographic variables that were assessed demonstrated statistically significant changes between the pre- and postoperative periods (Tables 1 and 2). Overall, 100% (51/51) of the operated feet went on to display radiographic osseous union, 2 (3.92%) of which displayed delayed unions (failure to demonstrate progressive radiographic changes consistent with arthrodesis after the 3-month postoperative interval). External bone stimulators were used in both delayed unions at the 14th postoperative week for 4 months in one case, and 5 months in the other. On comparison of the pre- and postoperative DP radiographs, repeated measures ANOVA of the percentage of talar head uncovering improved from a mean percentage of 40.14 ± 17.75 to 1.00 ± 2.36 ($P < .001$). The calcaneocuboid abduction angle improved from $28.30^{\circ} \pm 10.78^{\circ}$ to $5.80^{\circ} \pm 4.99^{\circ}$ ($P < .001$), Kite's angle improved from $22.60^{\circ} \pm 5.22^{\circ}$ to $10.90^{\circ} \pm 2.88^{\circ}$ ($P < .001$), and the talar–first metatarsal declination angle decreased from $12.70^{\circ} \pm 6.07^{\circ}$ to $1.70^{\circ} \pm 3.52^{\circ}$ ($P < .001$). On comparison of the pre- and postoperative lateral radiographs, the calcaneal inclination angle increased from $10.40^{\circ} \pm 7.05^{\circ}$ to $18.90^{\circ} \pm 6.05^{\circ}$ ($P < .001$), and the change in talar dome height increased from 7.10 ± 0.92 cm to 7.80 ± 0.77 cm ($P < .001$).

Table 2
Preoperative versus postoperative outcomes (N = 51 feet in 41 patients)

Variable	Preoperative	Postoperative	P value ^a
Talar uncovering (%)	40.14 ± 15.75	1 ± 2.36	<.001
Calcaneocuboid angle (°)	28.33 ± 10.78	5.80 ± 4.99	<.001
Kite's angle (°)	22.58 ± 5.22	10.94 ± 2.88	<.001
Talar dome height (mm)	7.09 ± 0.92	7.74 ± 0.77	<.001
Calcaneal inclination angle (°)	10.42 ± 7.05	18.94 ± 6.05	<.001
Meary's angle (°)	12.67 ± 6.07	1.74 ± 3.52	<.001
Pain Score ^b	7.6 ± 2.37	1.9 ± 2.38	<.001

^aRepeated measures analysis of variance.

^bPain Score = 10-point categorical pain score.

Discussion

The most immediate concern with any selected hindfoot arthrodesis is the limitation or elimination of motion, and the creation of additional stresses at adjacent joints. It has been demonstrated, however, that if the foot is placed in a well-aligned position, additional stresses and the development of adjacent arthritis can be minimized, perhaps even eliminated (22–24). This has also been seen in patients with asymptomatic tarsal coalitions, and has been described by Yu and Shook (22) as follows: “These occult conditions have remained silent for a lifetime...The reason for the lack of symptoms in this group of patients is that the foot is in a neutral position or the patient has experienced a developmental arthrodesis over time and has maintained relatively normal alignment of the foot. (p. 1194)” In the patients described in this investigation, the decision to undergo TN joint fusion was based on the presence of recalcitrant symptomatology, severe malposition, and joint instability. In essence, the goal of the procedure was to create a stable, well-positioned foot.

Most published reports regarding isolated TN arthrodesis deal with adults and associated rheumatoid arthritis, and this has been made clear by Weinheimer (25). As regards the arthritic TN joint, various articles have shown the effectiveness of arthrodesis at this level (26–30). Generally arthrodesis of an isolated, unstable, non-arthritic joint for the treatment of pes valgus is well accepted (ie, subtalar joint and medial column procedures); however, this is not the case for isolated TN joint fusion (21, 22, 31). One extensive literature review summarized the surgical techniques, outcomes, and complications associated with multiple operative procedures for pes valgus deformities (32). It included discussion of the isolated triple arthrodesis, triple arthrodesis with tarsometatarsal fusion, triple arthrodesis with lateral column lengthening, and an isolated subtalar fusion. Interestingly, there was no mention of using an isolated TN arthrodesis as a possibility for the treatment of severe adult-acquired pes planovalgus. This sentiment was noted in an earlier publication that discussed the complications of surgical treatments for adult pes valgus deformities (33). Overall, the surgical literature is somewhat lacking in regard to in-depth discussion based on even modest case reports of the potential benefits of isolated TN arthrodesis for the treatment of pediatric and/or adult pes valgoplanus deformity.

Lombardi, Dennis, Connolly, and Silhanek (34) reported the results of combined TN joint arthrodesis and Evans calcaneal osteotomy for the treatment of posterior tibial tendon dysfunction. At an average of 35 months follow-up, 10 of their patients demonstrated significant improvement in both their subjective discomfort and in the structural alignment and function of their feet. Their patients displayed an improvement in the average American Orthopaedic Foot & Ankle Society Ankle-Hindfoot Rating Scale when the pre- and postoperative (42.3/100 and 83.0/100, respectively) values were compared. Even though their sample size was relatively small and the follow-up period rather short, their results were favorable. Furthermore, they explained that their rationale for combining the TN fusion with the Evans calcaneal osteotomy was 2-fold. The Evans, they noted, was performed

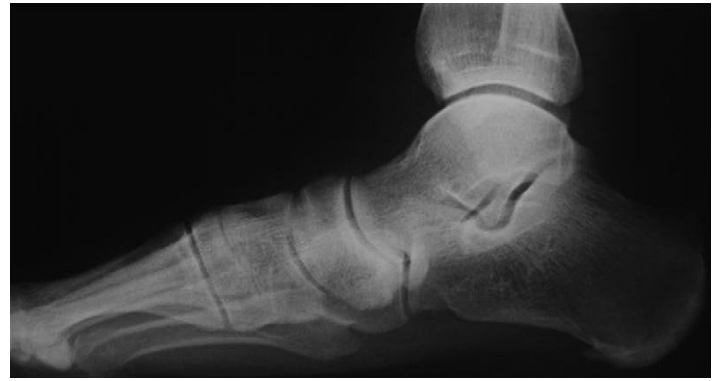

Fig. 1. Preoperative lateral radiograph of a 68-year-old female who presented with a painful collapsed pes valgus deformity. A decreased calcaneal inclination angle is visualized in addition to an increase in the talar-first metatarsal angle.

first, placing the foot in an improved position with the TN fusion performed to stabilize remaining instability if needed. Second, the authors remarked on the effectiveness of the Evans in regard to increasing the lever arm of peroneus longus; thus, at least theoretically, improving forefoot varus. Lombardi, Dennis, Connolly, and Silhanek further hypothesized that the combination of procedures was more effective than either alone, but only reported on the 2 procedures performed together. Further still, it is interesting to note that cadaveric studies have shown that the TN joint is the key articulation in the reciprocating subtalar and rearfoot joint complex (TN, talocalcaneal, and calcaneocuboid joints) (35, 36) and, as such, arthrodesis of the TN joint alone conveys the ability to both align and maintain rearfoot position. The results from the current study demonstrated improvements in talar head uncovering and calcaneocuboid abduction (Table 2), consistent with the procedure's ability to reduce substantial amounts of forefoot abduction (Figures 1 and 2). Similarly, the medial column was also restored on the lateral radiograph as demonstrated by improvement in the talar-first metatarsal declination angle (Table 2) (Figures 3 and 4). Based on the radiographic findings that we observed (Table 2), we believe that forefoot varus and forefoot abduction can be satisfactorily addressed with an isolated TN fusion without the need for adjunctive Evans osteotomy (Figures 5 and 6).

Mann and Beaman (37) recommended the combination of TN and calcaneocuboid arthrodeses for collapsed pes valgus deformities. They reported the results of 16 patients with a 4.5-year average follow-up period. Their rationale for adding a calcaneocuboid fusion was to eliminate lateral midfoot pain and to allow correction of greater amounts of forefoot varus. However, in our investigation, only 3.92% (2/51) of the patients complained of postoperative lateral column pain, and neither of these patients required further surgery. Mann and Beaman (37) also described an increased rate of nonunion following isolated TN fusion. Despite their findings, we only encountered 2 (3.92%) delayed unions postoperatively, and both of these resolved with extended non-weight bearing and the use of external pulsed electromagnetic field bone stimulation without the need for bone graft or bone graft substitutes, or implanted bone growth stimulation.

Fortin (38) reiterated some of the same concerns that Mann and Beaman (37) expressed with isolated TN fusions, and also noted an additional concern for the development of adjacent arthritis of the ankle, most often attributed to residual hindfoot valgus leading to valgus collapse of the ankle. Thus, he recommended the combination of TN fusion with medial displacement calcaneal osteotomy in the treatment of pes valgus in adults. In our follow-up, the mean average of which was 43.3 (range 11 to 113) months, we did not encounter any complaints of adjacent arthritis of the ankle and, unfortunately,

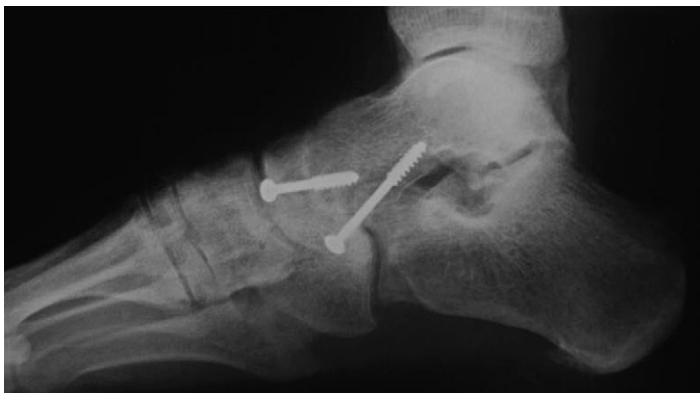

Fig. 2. A 1-year postoperative lateral radiograph demonstrating consolidation and correction following isolated talonavicular arthrodesis. Note the correction in the calcaneal inclination angle and the talar-first metatarsal angle.

calcaneal axial radiographs were not a component of our protocol so we were not able to indirectly compare our results with those related by Fortin (38). We did, however, encounter the development of post-surgical arthrosis involving the naviculocuneiform joint. In fact, 3.92% (2/51) of the feet upon which we operated underwent additional surgery for the treatment of painful naviculocuneiform arthritis following TN arthrodesis; and an additional 3.92% (2/51) feet also

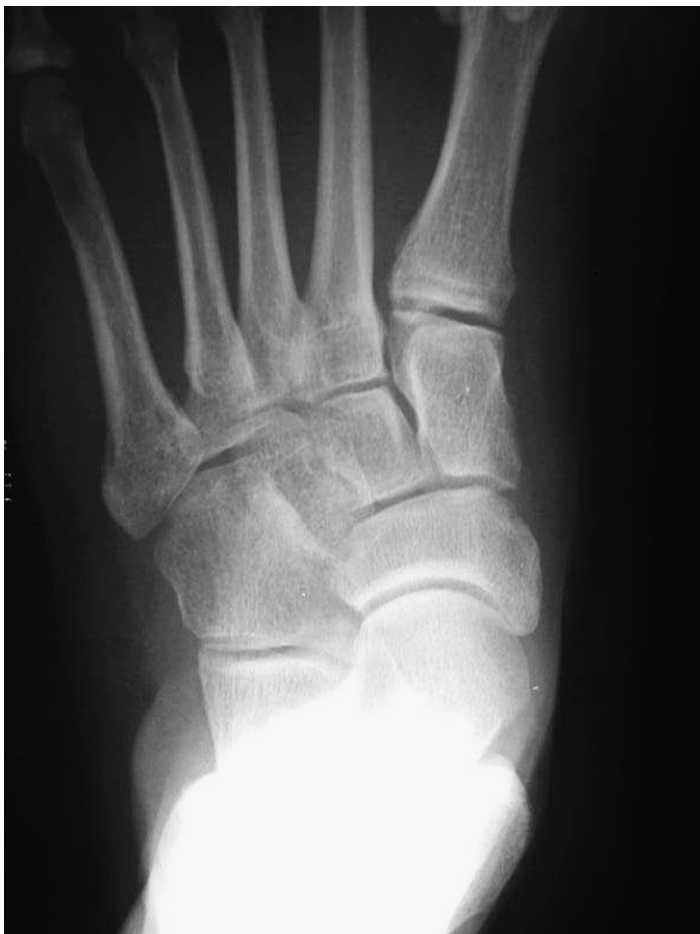

Fig. 3. Preoperative anteroposterior radiograph of a 68-year-old female who presented with a painful collapsed pes valgus deformity. Note the subluxation of the talar head from the navicular and the increase in Kite's angle.

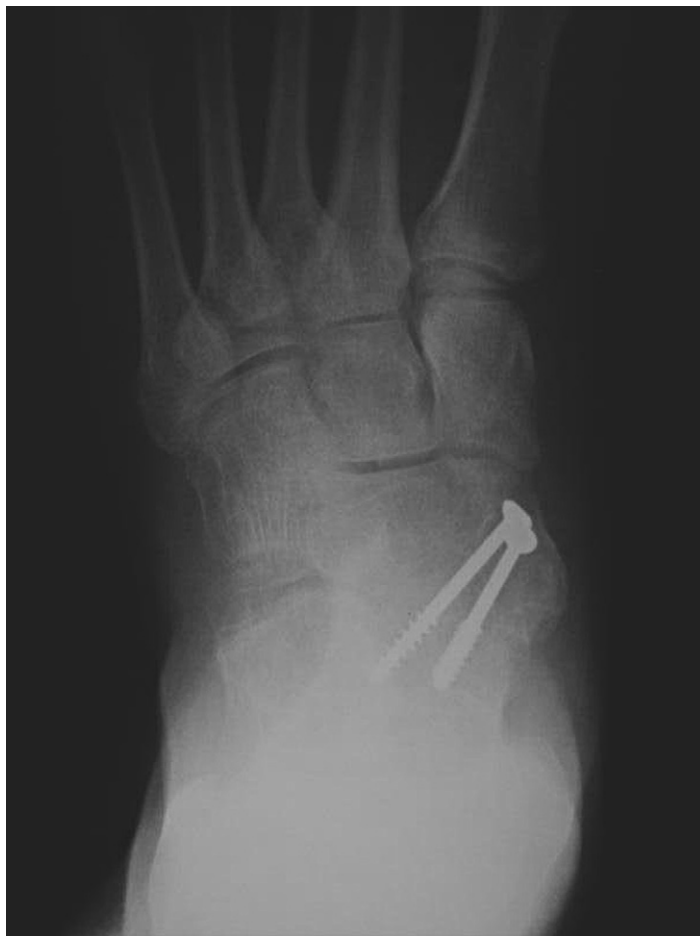

Fig. 4. A 1-year postoperative anteroposterior radiograph following isolated talonavicular arthrodesis. Note the relocation of the talar head behind the body of the navicular and the overall decrease in the Kite's angle.

developed subtalar joint arthritis, 1 of which required subsequent arthrodesis.

Harper (39) in 1996, and Harper and Tisdell (40) in 1999, reported on isolated TN fusions for the acquired adult flatfoot. In these 2 separate studies, a total of 55 adults, mean age 58 (range 39 to 74)

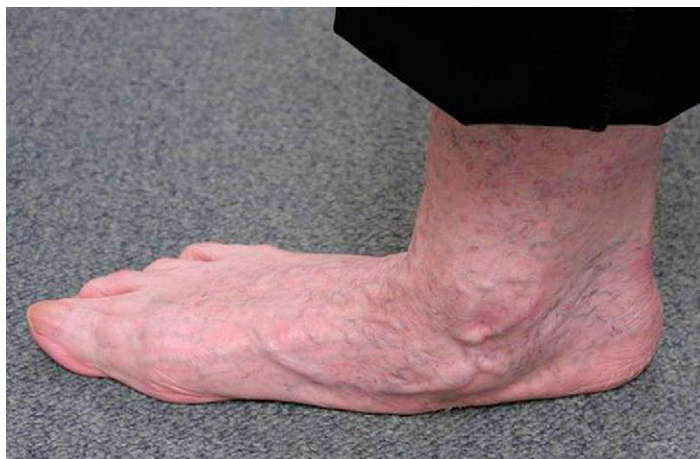

Fig. 5. A 68-year-old female with severe tibialis posterior tendon dysfunction and a collapsed pes valgus deformity. Note the severe pronation of the rearfoot and abduction of the forefoot.

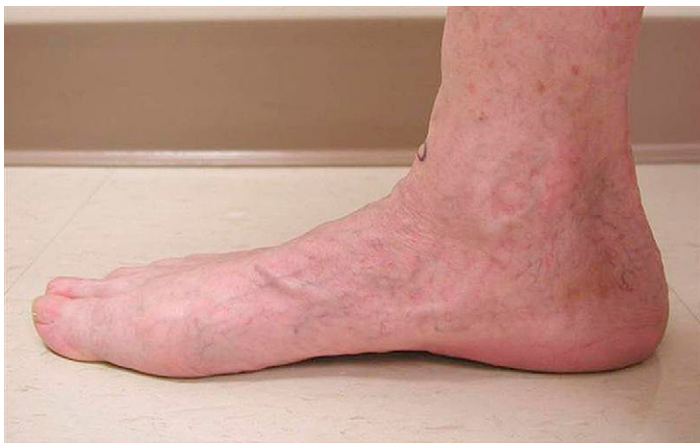

Fig. 6. At the 1-year follow-up visit, following talonavicular arthrodesis, note restoration of the patient's arch in comparison with the preoperative clinical view seen in Figure 5.

years, with painful flatfoot deformity were treated with TN fusions and followed postoperatively for an average of 26 and 27 months. In the first study, consisting of 26 patients, 92% (24/26) of the patients were rated as having either a good or excellent result, with either no pain or pain only after heavy weight-bearing activity. The repair, moreover, showed no evidence of deterioration of foot position for up to 5 years following the surgery. In the first case series, no bone graft was used for the first 6 patients; thereafter, iliac crest grafts were used in all patients. In the second case series, consisting of 29 patients, there was an overall satisfaction rate of 86% and the results were categorized as excellent in 11 patients, good in 14, and fair in 4 patients. Of particular interest, ankle motion was found to decrease an average 10° , and 6 patients developed adjacent arthrosis in the ankle, calcaneocuboid, naviculocuneiform, and tarsometatarsal joints following the TN fusion. Those authors speculated that excessive stress transferred to adjacent joints caused the transfer arthrosis, which was relatively mild, and they considered this to be a disadvantage of the procedure. The adult patients in these case series, however, were nonathletic, middle-aged or older individuals, and the loss of motion did not significantly alter their activities. The patients in both of these case series typically retained some limited hindfoot motion, whether through the subtalar joint or the ankle, or a combination of these joints. In both series, moreover, the authors concluded that TN arthrodesis was a valuable technique in treating the adult-acquired flatfoot deformity. The procedure addressed posterior tibial tendon abnormalities while providing reliable stability and reduced pain through a single approach with low morbidity.

In the cohort of patients described in this article, we observed a 100% rate of TN fusion. Despite this rate of union, we also observed a number of complications including bilateral delayed unions in a 65-year-old female. This particular patient required the use of an external bone growth stimulator, which was started on both feet at 14 weeks postoperatively. She required bone growth stimulation for 4 months on the left foot and 5 months on the right foot. She also had a 20-year history of smoking, but an otherwise unremarkable medical history. Only 2 other patients in our study were smokers, both had uneventful postoperative courses. Four patients (4 feet) developed secondary arthritic changes at the naviculocuneiform joint, 2 of which eventually required arthrodesis. Two patients (2 feet) developed subtalar joint pain; 1 resolved with a corticosteroid injection (1.0 mL marcaine 0.25% with epinephrine, 1.0 mL dexamethasone phosphate, and 0.25 mL dexamethasone acetate) and 1 required fusion. Four patients (4 feet) developed postoperative plantar heel pain that resolved with conservative treatment, and 3 patients (3 feet)

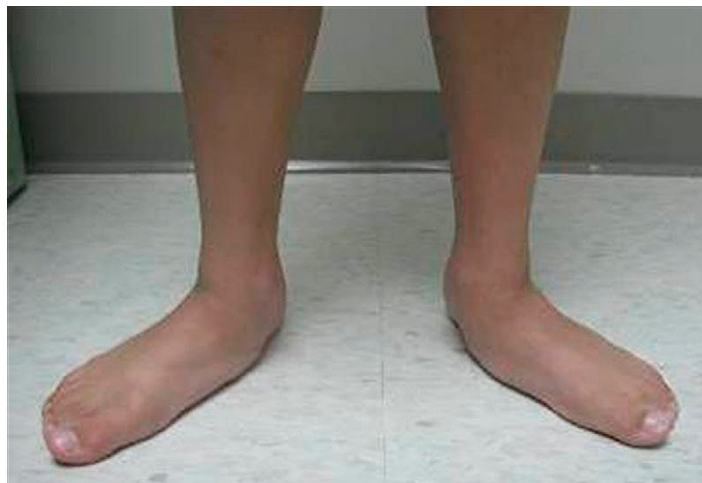

Fig. 7. A 12-year-old male patient with bilateral flexible collapsed pes valgus deformity.

developed superficial wound dehiscence that healed uneventfully. There were no postoperative infections, and none of the patients required removal of their internal fixation devices.

Our study involved a broader age range than did previously published reports, including 6 pediatric patients (10 feet), 4 of which underwent bilateral TN fusions (Figures 7 and 8). In all of the pediatric patients, activity levels increased postoperatively. The most common complaints among the pediatric patients were swelling after excessive activities and the encumbrance of using crutches during the recovery stages.

Among all patients analyzed in our cohort, 87.8% (36/41) of patients were satisfied with the procedure and would undergo the procedure again. A surprising complaint during the immediate postoperative recovery was difficulty ascending and descending stairs once weight bearing was initiated.

A number of methodological limitations influenced our investigation and may bias our conclusions. Chief among the shortcomings of this study is the fact that we did not have data related to foot-related quality of life as measured by a questionnaire that has been shown, in previous investigations, to provide valid data. A prospective study would have enabled us to more thoroughly define the variables that we consider to be clinically important in regard to the surgical treatment of pes valgus by means of arthrodesis. Although we could have undertaken a sensitivity analysis of our retrospective data, we felt that the radiographic and pain measurements were sufficient for our purposes in regard to this preliminary investigation of isolated TN fusion for the treatment of pes valgus. We used a 10-strata categorical pain scale, rather than the 10-cm visual analog scale (VAS), as the initial pain assessment documented in the record used the categorical system, and this may have limited our ability to more accurately ascertain the difference between pre- and postoperative pain. We also did not pursue explanatory analyses that may have shown whether or not a specific independent variable, or variables, statistically significantly influenced the outcomes that we observed. Moreover, as is often the case in retrospective case series, none of the outcomes assessors were blind to the intervention. Although this may have biased the radiographic measurements toward a treatment effect, the assessors participated in only a small number of the surgeries and were unaware of the future study. In addition the patient-controlled subjective pain measurement, we believe, was more important clinically. Furthermore, the duration of time between the TN fusion and the follow-up telephone interview may have been long enough that other influences could have biased the categorical pain measurement. We feel,

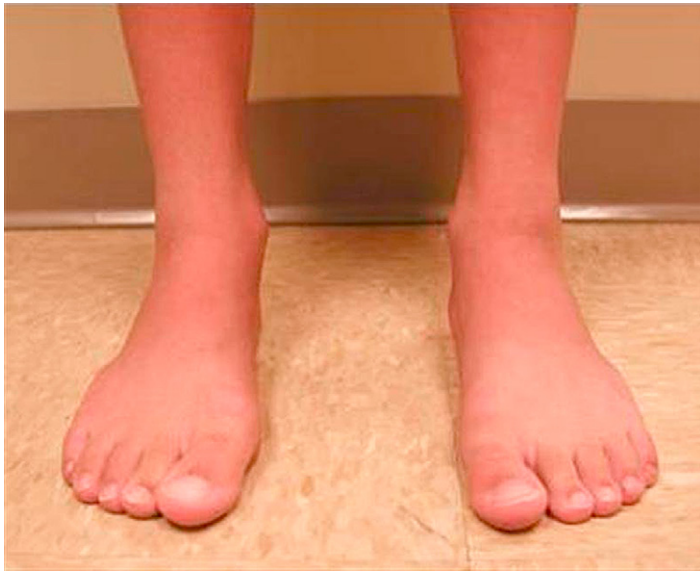

Fig. 8. At the 1-year follow-up visit, following bilateral talonavicular arthrodesis, note the improved alignment of the patient's feet.

however, that it would have been just as likely for progressive loss of correction and recurrence of symptoms to influence the outcome, and this would have biased toward a null effect of the arthrodesis. Last, because some of the patients who we evaluated had the surgery performed on both of their feet (at different times), and all of the patients were subjected to repeated measures, some of the data were linked (dependent) and all of it was subject to carryover effects, and these factors may have imparted some minor influences on our conclusions.

In summary, the authors evaluated the results of 51 isolated TN arthrodeses in 41 patients of various ages and, using repeated measures ANOVA, showed that all of the radiographic variables considered in the study were found to be statistically significantly improved between the pre- and postoperative periods. More importantly clinically, the mean pain level before the surgery statistically significantly improved from a preoperative value of 7.6 to a postoperative value of 1.9. Based on these results, we concluded that isolated TN arthrodesis is an effective intervention for the treatment of painful pes valgus deformity in pediatric and adult patients.

References

- McCormack AP, Ching RP, Sangeorzan BJ. Biomechanics of procedures used in adult flatfoot deformity. *Foot Ankle Clin* 6(1):15–23, 2001.
- Pedowitz WJ, Kovatis P. Flatfoot in the adult. *J Am Acad Orthop Surg* 3(5):293–302, 1995.
- van Boerum DH, Sangeorzan BJ. Biomechanics and pathophysiology of flat foot. *Foot Ankle Clin* 8(3):419–430, 2003.
- Meehan RE, Brage M. Adult acquired flat foot deformity: clinical and radiographic examination. *Foot Ankle Clin* 8(3):431–452, 2003.
- Johnson KA, Strom DE. Tibialis posterior tendon dysfunction. *Clin Orthop Relat Res* 239:196–206, 1989.
- Myerson MS. Adult acquired flatfoot deformity: treatment of dysfunction of the posterior tibial tendon. *Instr Course Lect* 46:393–405, 1997.
- Bluman EM, Myerson MS. Stage IV posterior tibial tendon rupture. *Foot Ankle Clin* 12(2):341–362, 2007.
- Banks AS, McGlamry ED. Tibialis posterior tendon rupture. *J Am Podiatr Med Assoc* 77(4):170–176, 1987.
- Mahan KT, Flanigan KP. In *McGlamry's Comprehensive Textbook of Foot and Ankle Surgery*, ed 3, vol. II, pp 799–862, edited by MS Downey, AS Banks, DE Martin, SJ Miller, Lippincott Williams & Wilkins, Philadelphia, 2001.
- Ananthakrishnan D, Ching R, Tencer A, Hansen ST Jr, Sangeorzan BJ. Subluxation of the talocalcaneal joint in adults who have symptomatic flatfoot. *J Bone Joint Surg Am* 81(8):1147–1154, 1999.
- Greisberg J, Assal M, Hansen ST Jr, Sangeorzan BJ. Isolated medial column stabilization improves alignment in adult-acquired flatfoot. *Clin Orthop Relat Res* 435:197–202, 2005.
- Cohen BE, Ogden F. Medial column procedures in the acquired flatfoot deformity. *Foot Ankle Clin* 12(2):287–299, 2007.
- Gallina J, Sands AK. Lateral-sided bony procedures. *Foot Ankle Clin* 8(3):563–567, 2003.
- Hintermann B, Valderrabano V, Kundert HP. Lengthening of the lateral column and reconstruction of the medial soft tissue for treatment of acquired flatfoot deformity associated with insufficiency of the posterior tibial tendon. *Foot Ankle Int* 20(10):622–629, 1999.
- Myerson MS, Badekas A, Schon LC. Treatment of stage II posterior tibial tendon deficiency with flexor digitorum longus tendon transfer and calcaneal osteotomy. *Foot Ankle Int* 25(7):445–450, 2004.
- Grumbine NA. Talar neck osteotomy for flatfoot reconstruction: a 27-year follow-up study. *Clin Podiatr Med Surg* 23(1):41–55, 2006.
- Labovitz JM. The algorithmic approach to pediatric flexible pes planovalgus. *Clin Podiatr Med Surg* 23(1):57–76, 2006.
- Mosier-LaClair S, Pomeroy G, Manoli A. Operative treatment of the difficult stage 2 adult acquired flatfoot deformity. *Foot Ankle Clin* 6(1):95–119, 2001.
- Greisberg J, Hansen ST, Sangeorzan B. Deformity and degeneration in the hindfoot and midfoot joints of the adult acquired flatfoot. *Foot Ankle Int* 24(7):530–534, 2003.
- Vora AM, Tien TR, Parks BG, Schon LC. Correction of moderate and severe acquired flexible flatfoot with medializing calcaneal osteotomy and flexor digitorum longus transfer. *J Bone Joint Surg Am* 88(8):1726–1734, 2006.
- Vulpius O, Stoffel A. *Orthopädische Operationslehre*. pp 29–31, Ferdinand Enke, Stuttgart, 1913.
- Yu GV, Shook JE. Selected rearfoot arthrodesis. In *McGlamry's Comprehensive Textbook of Foot and Ankle Surgery*, ed 3, vol. II, pp 1193–1218, edited by MS Downey, AS Banks, DE Martin, SJ Miller, Lippincott Williams & Wilkins, Philadelphia, 2001.
- Fishco WD, Cornwall MW. Gait analysis after talonavicular joint fusion: 2 case reports. *J Foot Ankle Surg* 43(4):241–247, 2004.
- Duncan JW, Lovell WW. Hoke triple arthrodesis. *J Bone Joint Surg Am* 60(6):795–798, 1978.
- Weinheimer D. Talonavicular arthrodesis. *Clin Podiatr Med Surg* 21(2):227–240, 2004.
- Fogel GR, Katoh Y, Rand JA, Chao EY. Talonavicular arthrodesis for isolated arthrosis: 9.5-year results and gait analysis. *Foot Ankle* 3(2):105–113, 1982.
- Elbar JE, Thomas WH, Weinfeld MS, Potter TA. Talonavicular arthrodesis for rheumatoid arthritis of the hindfoot. *Orthop Clin North Am* 7(4):821–826, 1976.
- Ljung P, Kaij J, Knutson K, Pettersson H, Rydholm U. Talonavicular arthrodesis in the rheumatoid foot. *Foot Ankle* 13(6):313–316, 1992.
- Potter TA. Talonavicular fusion with bone graft for spastic arthritic flat foot. *Surg Clin North Am* 49(4):883–887, 1969.
- Johnson JE, Yu JR. Arthrodesis techniques in the management of stage II and III acquired adult flatfoot deformity. *Instr Course Lect* 55:531–542, 2006.
- Hiller L, Pinney SJ. Surgical treatment of acquired flatfoot deformity: what is the state of practice among academic foot and ankle surgeons in 2002? *Foot Ankle Int* 24(9):701–705, 2003.
- Kadokia AR, Haddad SL. Hindfoot arthrodesis for the adult acquired flat foot. *Foot Ankle Clin* 8(3):569–594, 2003.
- Neufeld SK, Myerson MS. Complications of surgical treatments for adult flatfoot deformities. *Foot Ankle Clin* 6(1):179–191, 2001.
- Lombardi CM, Dennis LN, Connolly FG, Silhanek AD. Talonavicular arthrodesis and Evans calcaneal osteotomy for treatment of posterior tibial tendon dysfunction. *J Foot Ankle Surg* 38(2):116–122, 1999.
- Astion DJ, Deland JT, Otis JC, Kenneally S. Motion of the hindfoot after simulated arthrodesis. *J Bone Joint Surg Am* 79(2):241–246, 1997.
- O'Malley MJ, Deland JT, Lee KT. Selective hindfoot arthrodesis for the treatment of adult acquired flatfoot deformity: an in vitro study. *Foot Ankle Int* 16(7):411–417, 1995.
- Mann RA, Beaman DN. Double arthrodesis in the adult. *Clin Orthop Relat Res* 365:74–80, 1999.
- Fortin PT. Posterior tibial tendon insufficiency. Isolated fusion of the talonavicular joint. *Foot Ankle Clin* 6(1):137–151, 2001.
- Harper MC. Talonavicular arthrodesis for the acquired flatfoot in the adult. *Clin Orthop Relat Res* 365:65–68, 1999.
- Harper MC, Tisdell CL. Talonavicular arthrodesis for the painful adult acquired flatfoot. *Foot Ankle Int* 17(11):658–661, 1996.